

Overexpression of interleukin-1 β and interleukin-6 may play an important role in periodontal breakdown in type 2 diabetic patients

P. M. Duarte¹, M. C. G. de Oliveira²,
C. H. Tambeli³, C. A. Parada³,
M. Z. Casati⁴, F. H. Nociti Jr⁴

¹Department of Periodontics, Dental Research Division, Guarulhos University, Guarulhos, São Paulo, Brazil, ²Department of Physiological Sciences, Division of Physiology, School of Dentistry at Piracicaba, University of Campinas, Piracicaba, São Paulo, Brazil, ³Department of Pharmacology, Faculty of Medicine of Ribeirão Preto, University of São Paulo, Ribeirão Preto, São Paulo, Brazil and ⁴Department of Prosthodontics and Periodontics, Division of Periodontics, School of Dentistry at Piracicaba, University of Campinas, Piracicaba, São Paulo, Brazil

Duarte PM, de Oliveira MCG, Tambeli CH, Parada CA, Casati MZ, Nociti FH Jr. Overexpression of interleukin-1 β and interleukin-6 may play an important role in periodontal breakdown in type 2 diabetic patients. *J Periodont Res* 2007; 42: 377–381. © 2007 The Authors. Journal compilation © 2007 Blackwell Munksgaard

Background and Objective: This study evaluated whether the biochemical changes associated with type 2 diabetes modulate the expression of interleukin-1 β , interleukin-6, interleukin-8, and interferon- γ in sites with chronic periodontitis.

Material and Methods: Biopsies were harvested and divided into three groups: group 1, systemically and periodontally healthy subjects ($n = 10$); group 2, systemically healthy subjects with moderate-to-severe chronic periodontitis (probing depth > 6 mm) ($n = 20$); and group 3, type 2 diabetic subjects with periodontitis ($n = 20$). Cytokine levels were assessed in the gingival tissues by enzyme-linked immunosorbent assay analysis.

Results: Data analysis demonstrated that the interleukin-1 β , interleukin-6, interleukin-8, and interferon- γ levels were higher in the presence of periodontal inflammation than in the absence of inflammation, regardless of systemic status. The interleukin-1 β and interleukin-6 levels were higher in diabetic subjects (group 3) than in systemically healthy patients with comparable types of periodontitis (group 2). No difference was observed for the interleukin-8 and interferon- γ levels between groups 2 and 3.

Conclusion: Within the limits of this study, it was concluded that type 2 diabetes was associated with increased expression of interleukin-1 β and interleukin-6 in periodontally inflamed tissues of diabetic patients, relative to nondiabetic subjects, and that such overexpression may be involved in the mechanisms by which type 2 diabetes enhances periodontal destruction.

Francisco H. Nociti Jr, Avenue Limeira 901, Bairro Areia, CEP 13414–903, Piracicaba, São Paulo, Brazil
Tel: +55 19 2106 5298
Fax: +55 19 3412 5301
e-mail: nociti@fop.unicamp.br

Key words: cytokines; periodontitis; type 2 diabetes

Accepted for publication September 21, 2006

During recent years, the influence of systemic factors on the pathogenesis of periodontal disease has been assessed, and consistent evidence has been provided establishing both type 1 and type

2 diabetes mellitus as risk factors for the initiation and progression of periodontal disease. Type 2 diabetes, formerly known as noninsulin-dependent diabetes, represents the most common

type of diabetes, which is caused by resistance to insulin combined with a failure to produce enough insulin to compensate this resistance (1–6). Several mechanisms have been proposed to

explain the greater incidence and severity of periodontal disease in diabetic subjects (4–6). These include polymorphonuclear leukocyte dysfunction (7,8), vascular changes, altered collagen and glycosaminoglycan synthesis, deregulated cytokine production (9), and the formation of advanced glycation end-products (10). Advanced glycation end-products, through their receptors, induce the expression of pro-inflammatory cytokines, such as prostaglandin E₂, interleukin-1 β , interleukin-6, and tumor necrosis factor- α (11,12). Therefore, advanced glycation end-product–their receptors interaction amplifies the magnitude of cytokine expression and response, which may further amplify the progression and severity of periodontitis. Even though some studies have attempted to describe the role of diabetes mellitus in periodontal pathological processes, few have examined the presence of local expression of inflammatory factors in the periodontal tissue of type 2 diabetic patients. Therefore, the aim of this study was to evaluate whether type 2 diabetes mellitus is associated with altered expression of interleukin-1 β , interleukin-6, interleukin-8, and interferon- γ in sites with moderate-to-severe chronic periodontitis.

Material and methods

Study population

This study was approved by the Institutional Review Board of the University of Campinas School of Dentistry. All subjects were submitted to anamnesis and to clinical and periodontal examination (Table 1). Patients with moderate-to-severe chronic periodontitis were defined as having multiple sites (at least eight) with a probing depth of ≥ 6 mm that was associated with bleeding on probing, and with bone loss as determined by radiographs. Exclusion criteria included any systemic disorder that would require antibiotic prophylaxis or would affect the periodontitis condition, except for diabetes, and patients who received scaling and root planing and/or used systemic or subgingival antimicrobials

Table 1. Demographic clinical characteristics of the study populations for the three experimental groups (mean \pm SD)

	Group 1 (n = 10)	Group 2 (n = 20)	Group 3 (n = 20)
Age (years)	39.57 \pm 2.85	37.50 \pm 4.11	40.86 \pm 3.37
% male subjects	40.00	33.33	40.00
Probing depth (mm)	1.95 \pm 0.45	7.65 \pm 0.57	7.69 \pm 0.43
Glycemic level (mg/dL)	–	–	110.13 \pm 5.99
Duration of diabetes (years)	–	–	14.06 \pm 5.52

or anti-inflammatory medication within 6 mo prior to baseline examination. Only patients who had been diagnosed with type 2 diabetes mellitus for at least 10 years were classified as diabetic. All patients were nonsmoking, and female patients were not pregnant, lactating or using any method of birth control.

Experimental design and biopsy collection

Prior to biopsy collection, selected sites were dichotomously assessed for supragingival plaque and bleeding on probing. In addition, probing depth and attachment loss measurements were also obtained from sample sites (Table 2). Gingival biopsies were harvested from single teeth from subjects undergoing periodontal surgery for disease-related and nondisease-related reasons (e.g. esthetics). Following block anesthesia, tissues on tooth surfaces where periodontal pockets were evaluated were incised to include the entire soft tissue walls of the pockets to be investigated. The entire pocket and junctional epithelia, as well as the adjacent connective tissue, were carefully removed with a surgical blade. Biopsies were restricted to one or more sites around a randomly selected tooth and divided into three different groups according to their periodontal and systemic status, as follows.

Group 1 — Systemically and periodontally healthy subjects. These subjects had a high standard of oral hygiene with no bleeding on probing, and a probing depth of ≤ 3 mm in the selected sites (n = 10).

Group 2 — Subjects who were systemically healthy and clinically diagnosed with moderate-to-severe chronic periodontitis (e.g. probing depth ≥ 6 mm and bleeding on probing) (n = 20).

Group 3 — Type 2 diabetic subjects (actual fasting serum glucose levels < 120 mg/dL) clinically diagnosed with moderate-to-severe chronic periodontitis (n = 20).

Enzyme-linked immunoabsorbent assay (ELISA)

ELISA was performed as detailed in a previous report (13). Briefly, biopsies were stored at -20°C and homogenized in a solution of phosphate-buffered saline containing 0.4 M NaCl, 0.05% Tween 20, 0.5% bovine serum albumin, 0.1 mM phenylmethylsulfonyl fluoride, 0.1 mM benzotonic chloride, 10 mM EDTA, and 20 KIU/mL aprotinin (Sigma Chemical Co., St Louis, MO, USA). The samples were centrifuged (12,350 g, 15 min, 4°C) and the supernatant was used to evaluate the concentrations of interleukin-1 α , interleukin-

Table 2. Mean values (\pm SD) of clinical parameters of sampling sites for the three experimental groups

	Group 1 (n = 10)	Group 2 (n = 20)	Group 3 (n = 20)
Probing depth (mm)	1.35 \pm 0.90	7.60 \pm 0.86	7.45 \pm 1.42
Attachment loss (mm)	1.25 \pm 0.62	8.50 \pm 0.92	8.15 \pm 1.47
Plaque (%)	0	100	100
Bleeding on probing (%)	0	100	100

6, interleukin-8, and interferon- γ in the gingival tissues. Polystyrene high-binding 96-well microtiter plates (Nunc-Immuno Plate; Maxisorp, Rochester, NY, USA) were coated with capture antibody, polyclonal rabbit anti-interleukin-1 α (3 $\mu\text{g}/\text{mL}$; Pharmingen, San Diego, CA, USA), anti-interleukin-6 (1 $\mu\text{g}/\text{mL}$; Pharmingen), anti-interferon- γ (1 $\mu\text{g}/\text{mL}$; Pharmingen), and anti-interleukin-8 (1 $\mu\text{g}/\text{mL}$; Pharmingen), diluted in phosphate-buffered saline coating buffer. After overnight incubation at 4°C, the plates were washed (as in subsequent steps) with phosphate-buffered saline containing 0.05% Tween 20 and 0.4 M NaCl and then incubated in dilution buffer (phosphate-buffered saline containing 1.0% bovine serum albumin; 100 μL per well) for 2 h at room temperature to block nonspecific binding. After washing, samples (100 μL per well), or the serially diluted standards of interleukin-1 β (5000 pg/mL; Pharmingen), interleukin-6 (2000 pg/mL; Pharmingen), interleukin-8 (2000 pg/mL; Pharmingen) or interleukin-1 α (2000 pg/mL; Pharmingen) were added to the plates and incubated overnight at 4°C. After washing the plates, 100 μL of biotinylated sheep polyclonal antihuman interleukin-1 β (0.2 $\mu\text{g}/\text{mL}$; Pharmingen), interleukin-6 (1 $\mu\text{g}/\text{mL}$; Pharmingen), interleukin-8 (1 $\mu\text{g}/\text{mL}$; Pharmingen) or interleukin-1 α (1 $\mu\text{g}/\text{mL}$; Pharmingen) was added to each well and the plates were incubated for 1 h at room temperature. Color was developed by the use of peroxidase-conjugated streptavidin (1 : 200; 100 μL per well) (DAKO Corp., Carpinteria, CA, USA) for 30 min and, after washing, the chromogen, *o*-phenylenediamine-2HCL (Sigma) was incubated for 15 min. The reactions were quenched with 150 μL of 1.0 M sulphuric acid. The absorbance of each well was read in a microplate spectrophotometer at 490 nm, and the concentration of cytokines was calculated from a standard curve and expressed as pg/mg of tissue.

Statistical analysis

Data from ELISA analysis were averaged and an intergroup comparison

was performed by one-way analysis of variance ($\alpha = 0.05$). If statistical difference was detected, a pairwise multiple comparison test (Bonferroni *t*-test) was used to identify the difference among the groups.

Results

Clinical observations

The mean values (\pm standard deviation) for the clinical parameters in the selected population, demographic data, and glycemic data in diabetic and nondiabetic subjects, and clinical parameters of sampling sites for all the three experimental groups are given in Tables 1 and 2, respectively. With respect to the sampling sites, group 1 showed no signs of inflammation (e.g. bleeding on probing) and the absence of dental biofilm, whereas for both groups 2 and 3, inflammation and dental biofilm were always present. In addition, groups 2 and 3 showed a comparable type of periodontitis with respect to its type (chronic periodontitis) and severity (moderate to severe probing depth ≥ 6 mm).

ELISA analysis

The mean concentrations and standard deviation of interleukin-1 α , interleukin-6, interleukin-8, and interferon- γ levels in the gingival tissues for all the experimental groups are shown in Fig. 1. Data analysis demonstrated that interleukin-1 α , interleukin-6, interleukin-8, and interferon- γ levels were significantly increased by periodontal inflammation (groups 2 and 3), compared with the control group (group 1), regardless of systemic status ($p < 0.001$). In addition, interleukin-1 α and interleukin-6 levels were found to be higher in the gingival tissues harvested from periodontal sites in diabetic patients (group 3) compared to sites with a comparable type of periodontitis in the nondiabetic subjects (group 2) ($p < 0.05$). Finally, no significant difference was detected for interleukin-8 and interferon- γ levels between groups 2 and 3 ($p > 0.05$).

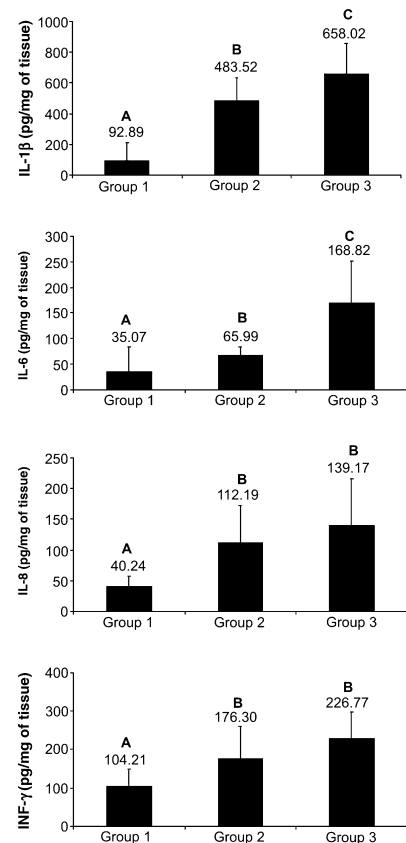


Fig. 1. Mean concentrations and standard deviations of interleukin-1 β , interleukin-6, interleukin-8, and interferon- γ (pg/mg of tissue), as determined by enzyme-linked immunosorbent assay, in gingival biopsies harvested from healthy periodontal sites (group 1), from systemically healthy subjects with moderate-to-severe chronic periodontitis (group 2), and from sites with comparable types of periodontitis in type 2 diabetic subjects (group 3). Different letters indicate statistical differences, as determined by an intergroup analysis using one-way analysis of variance ($\alpha = 0.05$), followed by a pairwise multiple comparison test (Bonferroni *t*-test), to identify the difference among the groups. IL, interleukin; IFN, interferon.

Discussion

The findings of the current study demonstrate that elevated levels of interleukin-1 β , interleukin-6, interleukin-8, and interferon- γ are more significantly associated with sites showing periodontal inflammation in comparison with noninflamed sites. In addition, data analyses suggest that an

overproduction of the pro-inflammatory cytokines interleukin-1 α and interleukin-6 in the local area may be involved in the type 2 diabetes modulation of periodontal destruction induced by the dental biofilm, whereas interleukin-8 and interferon- γ may not be directly involved. Interleukin-1 β is a bone-resorptive cytokine that also mediates soft-tissue destruction by stimulating the production of prostaglandin E and collagenase (14). It has been previously demonstrated that human gingival crevicular fluid from diabetic patients may contain higher levels of both prostaglandin E₂ and interleukin-1 α than the gingival crevicular fluid from healthy subjects (11). Furthermore, monocytes isolated from periodontal patients with type 1 diabetes produce significantly greater amounts of tumor necrosis factor- α , interleukin-1 α , and prostaglandin E₂ in response to lipopolysaccharide compared with nondiabetics (15). The findings of the present study suggest that, similarly to type 1 diabetes, type 2 diabetes mellitus may also be associated with locally elevated levels of interleukin-1 α at periodontal sites. These data corroborate those of Bulut *et al.* (16), who also observed that interleukin-1 α levels in the gingival crevicular fluid of type 2 diabetic patients were significantly higher than those in healthy individuals with and without periodontitis.

Interleukin-6 plays an important role in many chronic inflammatory diseases, being involved in leukocyte recruitment, apoptosis, and T-cell activation (17,18). In addition, a combination of interleukin-6 and its soluble receptor induce bone resorption either by increasing receptor activator of nuclear factor- κ B ligand (RANKL) or by directly acting on osteoclast formation (19–21). In the present study, data analysis suggests that high levels of interleukin-6 at the periodontal sites from diabetic patients may be relevant for type 2 diabetes modulation of periodontal disease. In line with the findings of this investigation, previous studies have demonstrated increased levels of interleukin-6 associated with periodontal sites in type 2 diabetic subjects (22,23).

Interleukin-8 plays a key role in the host defense mechanism in inflammatory diseases, including periodontitis, through neutrophil or nonleukocytic cell chemoattraction and activation (24–26). Interferon- γ is another key inflammatory mediator that is involved in T-cell-mediated activation of macrophages and bone remodeling (21,27,28). Furthermore, a recent clinical study suggested that the high level of expression of interferon- γ in salivary samples from type 2 diabetic patients may be associated with severe, but not with moderate, periodontitis (29). The results of the present study demonstrated that both interleukin-8 and interferon- γ levels were higher in the inflamed vs. noninflamed tissues, regardless of the diabetic state. Therefore, based on these data, although interleukin-8 and interferon- γ locally delivered in the gingival tissues play a relevant role in the pathogenesis of periodontal disease, they may not be directly involved in the mechanisms by which periodontal bone destruction is modulated in type 2 diabetic patients. In conclusion, within the limits of the present study, it may be concluded that overexpression of interleukin-1 β and interleukin-6 play a relevant role in the increased periodontal breakdown seen in individuals with type 2 diabetes mellitus. If these findings are confirmed by other studies, they may be helpful in designing more mechanistic approaches in order to minimize the negative effect of type 2 diabetes mellitus on periodontal destruction.

Acknowledgements

This project was supported by the São Paulo State Research Foundation (04/02436-1). Dr Nociti Jr was supported by the National Council of Research (304464/03-1).

References

1. Nelson R, Shlossman M, Budding L *et al.* Periodontal disease and NIDDM in Pima Indians. *Diabetes Care* 1990;**13**:836–840.
2. Firatli E, Yilmaz O, Onan U. The relationship between clinical attachment loss and the duration of insulin-dependent diabetes mellitus (IDDM) in children and

- adolescents. *J Clin Periodontol* 1996;**23**:362–366.
3. Reaven GM. Pathophysiology of insulin resistance in human disease. *J Clin Invest* 2000;**106**:473–481.
4. Tsai C, Hayes C, Taylor GW. Glycemic control of type 2 diabetes and severe periodontal disease in the US adult population. *Community Dent Oral Epidemiol* 2002;**30**:182–192.
5. Enrich LJ, Shlossman M, Genco RJ. Periodontal disease in non-insulin-dependent diabetes mellitus. *J Periodontol* 1991;**62**:123–131.
6. Taylor G, Burt B, Becker M *et al.* Non-insulin dependent diabetes mellitus and alveolar bone loss progression over 2 years. *J Periodontol* 1998;**69**:76–83.
7. Mowat A, Baum J. Chemotaxis of polymorphonuclear leukocytes from patients with diabetes mellitus. *N Engl J Med* 1971;**284**:621–627.
8. Manouchehr-Pour M, Spagnuolo PJ, Rodman HM, Bissada NF. Impaired neutrophil chemotaxis in diabetic patients with severe periodontitis. *J Dent Res* 1981;**60**:729–730.
9. Naguib G, Al-Mashat H, Desta T, Graves DT. Diabetes prolongs the inflammatory response to a bacterial stimulus through cytokine dysregulation. *J Invest Dermatol* 2004;**123**:87–92.
10. Lalla E, Lamster I, Feit M *et al.* Blockade of RAGE suppresses periodontitis associated bone loss in diabetic mice. *J Clin Invest* 2000;**105**:1117–1124.
11. Salvi G, Yalda B, Collins J *et al.* Inflammatory mediator response as a potential risk marker for periodontal diseases in insulin-dependent diabetes mellitus patients. *J Periodontol* 1997;**68**:127–135.
12. Salvi GE, Beck JD, Offenbacher S. PGE₂, IL-1 beta, and TNF-alpha responses in diabetics as modifiers of periodontal disease expression. *Ann Periodontol* 1998;**3**:40–50.
13. Safieh-Garabedian B, Poole S, Allechorne A, Winter J, Woolf CJ. Contribution of interleukin-1 beta to the inflammation-induced increase in nerve growth factor levels and inflammatory hyperalgesia. *Br J Pharmacol* 1995;**115**:1265–1275.
14. Richards D, Rutherford RB. The effects of interleukin 1 on collagenolytic activity and prostaglandin-E secretion by human periodontal-ligament and gingival fibroblast. *Arch Oral Biol* 1988;**33**:237–243.
15. Salvi GE, Collins JG, Yalda B, Arnold RR, Lang NP, Offenbacher S. Monocytic TNF alpha secretion patterns in IDDM patients with periodontal diseases. *J Clin Periodontol* 1997;**24**:8–.
16. Bulut U, Develioglu H, Taner IL, Berker E. Interleukin-1 beta levels in gingival crevicular fluid in type 2 diabetes mellitus

- and adult periodontitis. *J Oral Sci* 2001; **43**:171–177.
17. Scheller J, Ohnesorge N, Rose-John S. Interleukin-6 trans-signalling in chronic inflammation and cancer. *Scand J Immunol* 2006; **63**:321–329.
 18. Doganci A, Sauer K, Karwot R, Finotto S. Pathological role of IL-6 in the experimental allergic bronchial asthma in mice. *Clin Rev Allergy Immunol* 2005; **28**:257–270.
 19. Mihara M, Moriya Y, Kishimoto T, Ohsugi Y. Interleukin-6 (IL-6) induces the proliferation of synovial fibroblastic cells in the presence of soluble IL-6 receptor. *Br J Rheumatol* 1995; **34**:321–325.
 20. Kwan Tat S, Padrines M, Theoleyre S, Heymann D, Fortun Y. IL-6, RANKL, TNF-alpha/IL-1: interrelations in bone resorption pathophysiology. *Cytokine Growth Factor Rev* 2004; **15**:49–60.
 21. Baker PJ, Dixon M, Evans RT, Dufour L, Johnson E, Roopenian DC. CD4(+) T cells and the proinflammatory cytokines gamma interferon and interleukin-6 contribute to alveolar bone loss in mice. *Infect Immun* 1999; **67**:2804–2809.
 22. Cutler CW, Machen RL, Jotwani R, Iacopino AM. Heightened gingival inflammation and attachment loss in type 2 diabetics with hyperlipidemia. *J Periodontol* 1999; **70**:1313–1321.
 23. Kurtis B, Develioglu H, Taner IL, Balos K, Tekin IO. IL-6 levels in gingival crevicular fluid (GCF) from patients with non-insulin dependent diabetes mellitus (NIDDM), adult periodontitis and healthy subjects. *J Oral Sci* 1999; **41**:163–167.
 24. Atta-ur-Rahman, Harvey K, Siddiqui RA. Interleukin-8: An autocrine inflammatory mediator. *Curr Pharm Des* 1999; **5**:241–253.
 25. Mukaida N. Interleukin-8: an expanding universe beyond neutrophil chemotaxis and activation. *Int J Hematol* 2000; **72**:391–398.
 26. Gamodal J, Acevedo A, Bascones A, Jorge O, Silva A. Characterization of cellular infiltrate, detection of chemokine receptor CCR5 and interleukin-8 and RANTES chemokines in adult periodontitis. *J Periodont Res* 2001; **36**:194–203.
 27. Fox SW, Chambers TJ. Interferon- γ directly inhibits TRANCE-induced osteoclastogenesis. *Biochem Biophys Res Commun* 2000; **276**:868–872.
 28. Teng YT, Mahamed D, Singh B. Gamma interferon positively modulates *Actinobacillus actinomycetemcomitans*-specific RANKL+ CD4+ Th-cell-mediated alveolar bone destruction *in vivo*. *Infect Immun* 2005; **73**:3453–3461.
 29. Gomes MAB, Rodrigues FH, Afonso-Cardoso SR *et al*. Levels of immunoglobulin A1 and messenger RNA for interferon γ and tumor necrosis factor α in total saliva from patients with diabetes mellitus type 2 with chronic periodontal disease. *J Periodont Res* 2006; **41**:177–183.